



DATE PRESENTING CLINICAL SIGNS

1.5.26

PATIENT

Jackson Werneke

SPECIES

Canine

BREED

Chinese Crested

SEX

MN

AGE

1.3.16

WEIGHT

14.8lbs

INTERPRETED BY

Maggie Machen Lamy,
DVM, DACVIM
(Cardiology)

History: Presenting for recheck after ER visit for aspiration pneumonia and chronic vomiting. Has been drinking water excessively, then vomiting, and suspect that's what led to the pneumonia. However, at ER they also noted that the liver looked big, and recommended ultrasound with rDVM once P was feeling better. VEG recommended abx until 2 weeks after resolution of clinical signs. Still has occasional cough (could be related to the murmur as well), sent home another 2 weeks of abx and then recommended O's call to check in to see if symptoms aren't resolved by that time. ER recommended HP diet in case vomiting is food related, but O home cooks chicken and rice with pumpkin and doesn't think that the vomiting is food related. Declined prescription diet for now. History of seizures, 2-3 per month; each 2-3 minutes long - managed on Pheno and Potassium Bromide. Last Pheno levels were in July, consider recheck within the next couple of months (O's declined today to focus on the Pneumonia). Grade 3-4/6 heart murmur.
-Pertinent abnormal PE/Chem/CBC/UA Results: Elevated platelets (628) and ALT (142).
-Current medications: KBR 90mg CLAVACILLIN 125MG TABLET, ONDANSETRON 4MG TABLET, PHENOBARBITAL 15/16.2MG (1/4 GRAIN) TABLET.
-Sedation used: Not required to complete full diagnostic ultrasound.
-Pertinent previous ultrasound results: No previous.
-STAT: Not requested.
-Imaging performed by: Stephanie Warga RDCS, RVT.

RADIOGRAPHIC FINDINGS *NOTE: Images submitted for supplemental information only.

Normal cardiac silhouette. No obvious evidence of CHF.

ECHOCARDIOGRAM FINDINGS

2D, m-mode, color flow and doppler imaging is available. Mild diffuse thickening of mitral valve leaflets with mild prolapse into the left atrial lumen. Mild eccentric mitral regurgitation with mild left atrial dilation. Elevated MR velocity. Normal LV diameter with adequate myocardial function. The tricuspid valve appears normal with trace tricuspid regurgitation. Mildly elevated velocity, consistent with early pulmonary hypertension. Normal right atrial and ventricular diameter and morphology. The pulmonic and aortic valves are normal in morphology and mobility. Normal pulmonic and aortic outflow velocities with laminar flow. No obvious aortic or pulmonic insufficiency. No pericardial or pleural effusion noted. No obvious cardiac masses.

CARDIAC CHART

HOSPITAL NAME

Everhart VH

REFERRING VET

Dr. McDonald

INVOICE

46293

CANINE CARDIAC PARAMETERS	MR VMAX (m/s)	TR VMAX (m/s)	LA/AO (Boon method)	LA/AO (Heart Base; Swe)	FS (%)	EF (%)	EPSS (cm)
NORMAL PARAMETER	4.5-5.5	<2.7	1.3	<1.6	28-40	40-100	<0.6
PATIENT	6.5	3.3	NM	1.45	33	64	NM
CANINE CARDIAC PARAMETERS	HR (BPM)	AV VMAX (m/s)	PV MAX (m/s)	BODY WEIGHT (kg)	LA 2D short axis Base view (cm)	LVIDd Avg; 2D and m-mode short axis (cm)	LVIDs Avg; 2D and m-mode short axis (cm)
NORMAL PARAMETER	50-100	0.7-1.7	0.7-1.6	BELOW	BELOW	BELOW	BELOW
PATIENT	200	1.9	1.3	6.7	1.8	2.4	1.6
*Normal chamber parameters expressed as a mean value (SD)				3	1.27 (5.3)	2.46 (2.46)	1.36 (5.5)
				5	1.40 (4.5)	2.74 (5.2)	1.60 (4.7)

BODY WEIGHT DEPENDENT PARAMETERS	10	150 (3.8)	3.27 (3.5)	2.06 (3.1)
<i>*Note: All measurements based upon multi-modal images and methods. An average value is reported.</i>	15	1.83 (2.0)	3.71 (2.4)	2.43 (2.1)
	20	2.02 (1.9)	4.14 (2.2)	2.80 (2.0)
	25	2.18 (2.4)	4.48 (2.9)	3.10 (2.5)
Adapted from June Boon, Veterinary Echocardiography, 1998	30	2.33 (3.3)	4.83 (3.9)	3.39 (3.4)
Rishniw M and Hollis NE, J Vet Intern Med 2000; 14:429-435	35	2.48 (4.3)	5.17 (5.0)	3.69 (4.5)
Hansson et al, Vet Rad and Ultrasound 2002	40	2.62 (5.2)	5.48 (6.1)	3.96 (5.4)
Bonagura et al. Echocardiography: principles of interpretation, Vet Clin North Am 15:1177, 1995	50	2.88 (7.1)	6.07 (8.3)	4.46 (7.4)

INTERPRETATION OF THE FINDINGS & FURTHER RECOMMENDATIONS

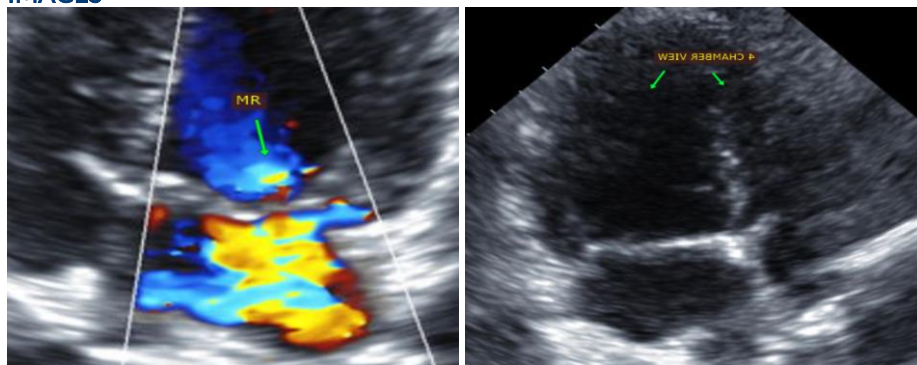
Chronic degenerative valve disease causing mild mitral and trace tricuspid regurgitation. Lack of significant left atrial enlargement indicates the current risk for complication is low. The MR velocity is elevated, and a baseline BP is recommended. The TR is also elevated, consistent with early pulmonary hypertension. This is of unknown significance in a dog without significant respiratory disease. Simple monitoring is advised. No additional issues are noted in this study.

In a dog with no significant left atrial enlargement, no cardiac medications are clearly indicated. Assessment of progression in the future will help predict long term prognosis, which is highly variable at this stage (B1). Omega fatty acid supplementation and mild salt restriction may be of some long-term benefit. Monitor for development of a cough, labored breathing, exercise intolerance or collapse episodes.

Anesthetic risk is considered mild if needed. Cardiac protective drug choices (opioid/benzodiazepine premedication, propofol or alfaxalone induction, isoflurane gas) are recommended. Pre-oxygenate for 5-10 minutes prior to induction. Monitor for arrhythmias, hypotension, and hypoxia both intra and post-operatively and intervene as necessary. Mild IV fluid restriction is recommended to avoid fluid overload. Avoid heart rate stimulating drugs such as atropine unless clinically indicated.

Recommend conservative monitoring with a recheck echocardiogram in 6 months, sooner if any development of clinical signs.

IMAGES



The information and recommendations provided are based on the images presented by the referring veterinarian. No evaluation can be communicated regarding pathology that was not visible in the image/video clips provided.

Thank you for this referral. This report was generated using transcription software, and minor dictation errors may be present. If the clinical or image interpretation does not parallel your findings or if I can be of any further assistance, please contact me.

**Maggie Machen Lamy, DVM
Diplomate of the American College of Veterinary Internal Medicine (Cardiology)
info@sonopath.com**